



PATIENT **ULTRASONOGRAPHIC EXAMINATION OF THE ABDOMEN**

Gambi Hong History: Not moving. Sitting with sternal position. Not eating for 2 days, blood tinged loose bowel movement

SPECIES *Urinary System*

Canine The urinary bladder is full with a normal thickness and smooth appearance of the wall. Moderate amount of floating hyperechogenic sediment present. No uroliths evident.

BREED

Normal appearance of the trigone area, proximal urethra, and iliac blood vessels.

CKC Spaniel

Normal appearance and size of the iliac lymph nodes (left: 4.80 cm / right: 5.00 cm). Ureters not visualized, which can be considered a normal finding.

SEX

Normal renal size, architecture, echogenic appearance, cortico-medullary differentiation, which maintains a 1:3 cortex to medulla ratio, pelvis, and capsule. No infarcts, mineralization or renoliths evident.

Intact Male

Reproductive System

Small hypoechoic prostate.

AGE

Adrenal Glands

13 years, 1 mo

Normal shape, echogenic appearance, size (left: 1.69 cm x 0.37 cm / right: 1.10 cm x 0.30 cm), position, and appearance of the visible peri-renal vasculature.

WEIGHT

Spleen

16.8 lbs

Normal size and echogenic appearance. Smooth homogenous parenchyma and regular curvilinear capsule. Normal volume of the splenic vasculature without any overt congestion or thrombosis evident. No inflammatory, neoplastic, infarction, or infiltrative changes evident.

INTERPRETED BY

Liver

Remo Lobetti, BVSc,
MMedVet (Med),
PhD, Dipl. ECVIM

Normal size, echogenic appearance, portal markings, and regular curvilinear capsule. No nodules or masses evident. Normal appearance of the hepatic and portal vasculature.

Gallbladder

The gallbladder is full containing small amount of hyperechogenic sediment. Normal thickness and echogenic appearance of the wall. Normal size and appearance of the cystic and common bile duct.

IMAGING PERFORMED BY

Gastrointestinal

Dr. Paul Kim

Focal thickening of the gastric wall (up to 1.00 cm with loss of layering), ingesta-filled stomach, duodenum, jejunum, small intestine, ileo-cecal junction, and colon with no loss of layering, 1:3 muscularis to mucosa ratio, normal wall thickness and peristaltic activity, and no distension of the lumen.

HOSPITAL NAME

Pancreas

Ridgefield Park AH

Normal size and echogenic appearance (left: 0.40 cm / right: 0.70 cm). Regular capsule. Normal echogenic appearance of the mesentery and fat surrounding the pancreas.

REFERRING VET

Free Abdomen

Dr. Paul Kim

Normal mesenteric lymph nodes.

No ascites evident.

INVOICE

13347

DATE

6.14.23



PATIENT

Gambi Hong

ULTRASONOGRAPHIC FINDINGS

Primary Findings

SPECIES

- Gastric thickening

Canine

Primary Findings

- Urinary and gallbladder sediment.

BREED

CKC Spaniel

INTERPRETATION OF THE FINDINGS & FURTHER RECOMMENDATIONS

Etiologies for the stomach would be helicobacter gastritis, inflammatory bowel disease, granulomatous enteritis, ulcerative disease and focal neoplasia.

SEX

Intact Male

Further assessment would be urine and fecal analysis, urine culture, FNA cytology of the gastric wall, and possibly gastroscopy with biopsies.

AGE

13 years, 1 mo

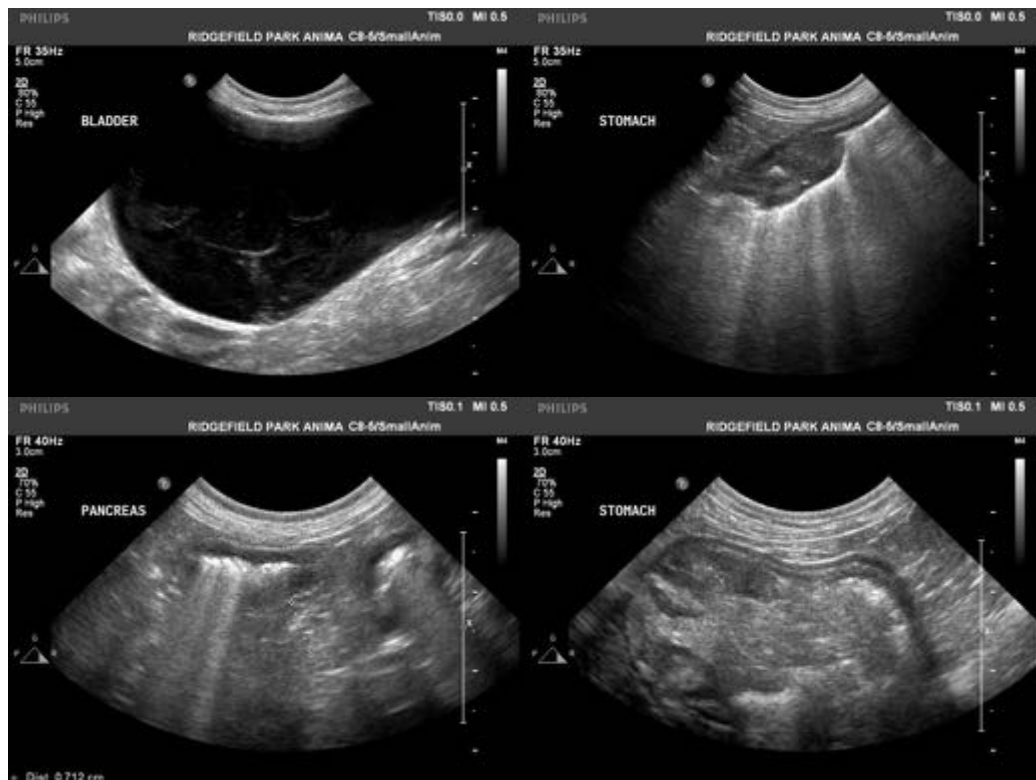
Specific therapy would be dependent on an etiological diagnosis. Symptomatic management would be gastric protectants (omeprazole, sucralfate), and possible metoclopramide.

WEIGHT

16.8 lbs

INTERPRETED BY

Remo Lobetti, BVSc,
MMedVet (Med),
PhD, Dipl. ECVIM



IMAGING PERFORMED BY

Dr. Paul Kim

HOSPITAL NAME

Ridgefield Park AH

REFERRING VET

Dr. Paul Kim

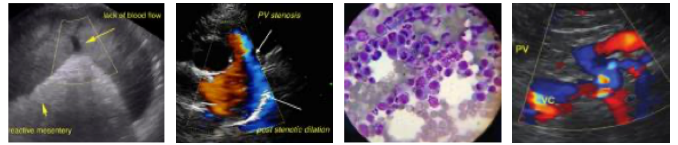
The information and recommendations provided are based on the images presented by the referring veterinarian. No evaluation can be communicated regarding pathology that was not visible in the image/video clips provided.

INVOICE

13347

DATE

6.14.23



PATIENT

Thank you for this referral. If the clinical or image interpretation does not parallel your findings or if I can be of any further assistance, please contact me.

Gambi Hong

Remo Lobetti, BVSc, MMedVet (Med), PhD, Dipl. ECVIM (Internal Medicine)
info@sonopath.com

SPECIES

Canine

BREED

CKC Spaniel

SEX

Intact Male

AGE

13 years, 1 mo

WEIGHT

16.8 lbs

INTERPRETED BY

Remo Lobetti, BVSc,
MMedVet (Med),
PhD, Dipl. ECVIM

**IMAGING
PERFORMED BY**

Dr. Paul Kim

HOSPITAL NAME

Ridgefield Park AH

REFERRING VET

Dr. Paul Kim

INVOICE

13347

DATE

6.14.23